



中华医学会核医学分会第十一届委员会 技术与继续教育学组

北京继续教育疑难病例分析展示

Interesting and Unusual Cases (25-31)

专家姓名: Leonard Freeman MD, PhD

专家单位: Division of Nuclear Medicine,
Albert Einstein College of Yeshiva University



中华医学会核医学分会
技术与继续教育学组

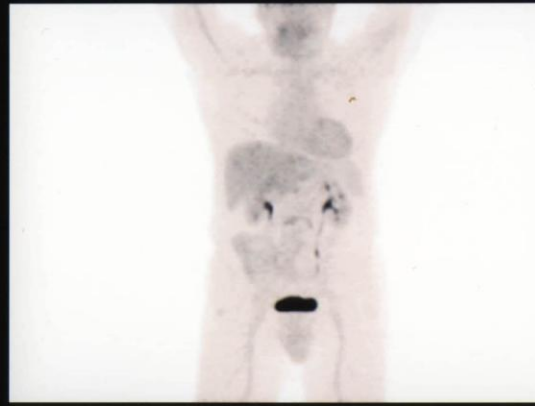
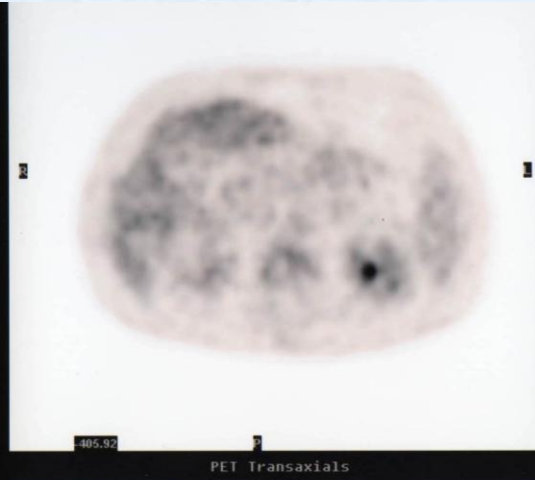
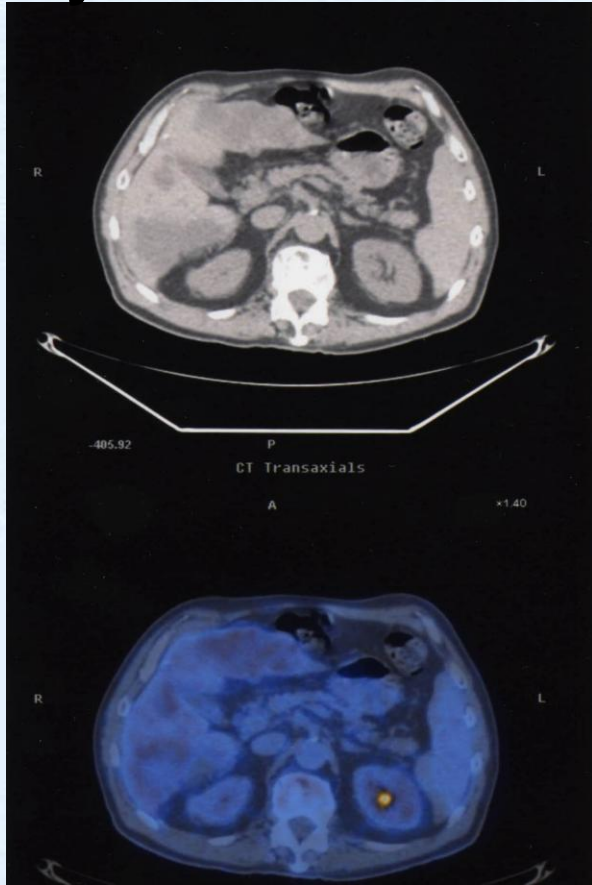


Albert Einstein College of Medicine
OF YESHIVA UNIVERSITY

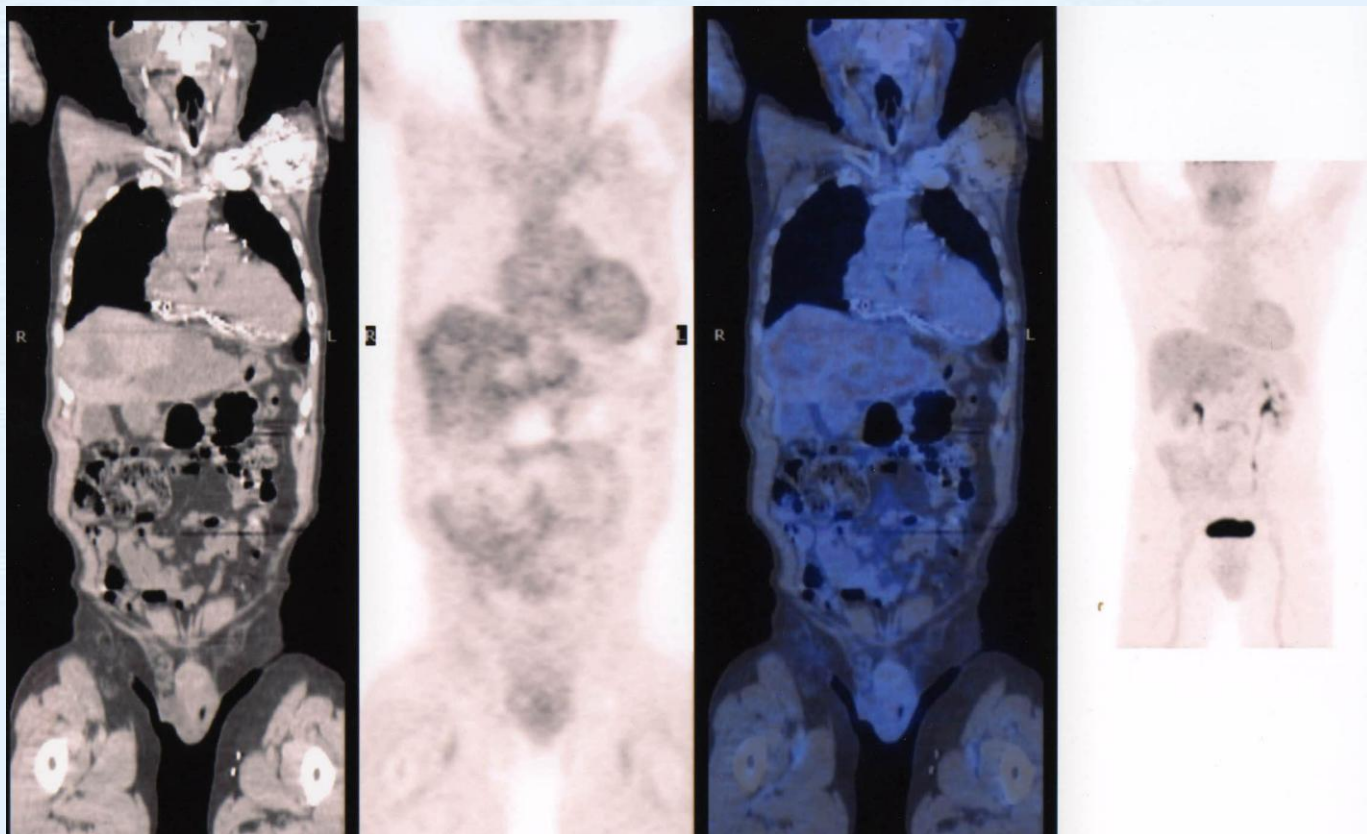


Case # 25

51 year old male with known cancer



51 year old man with known cancer



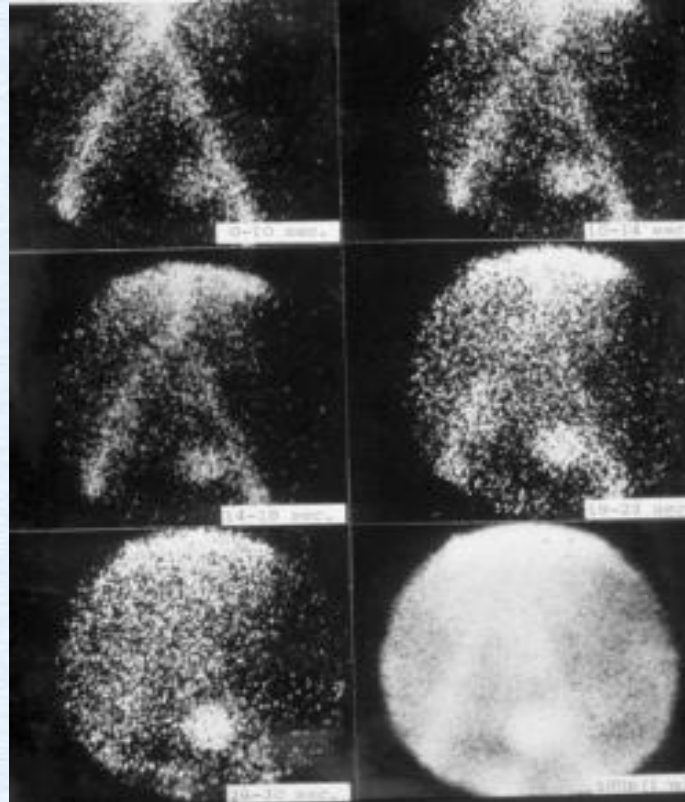


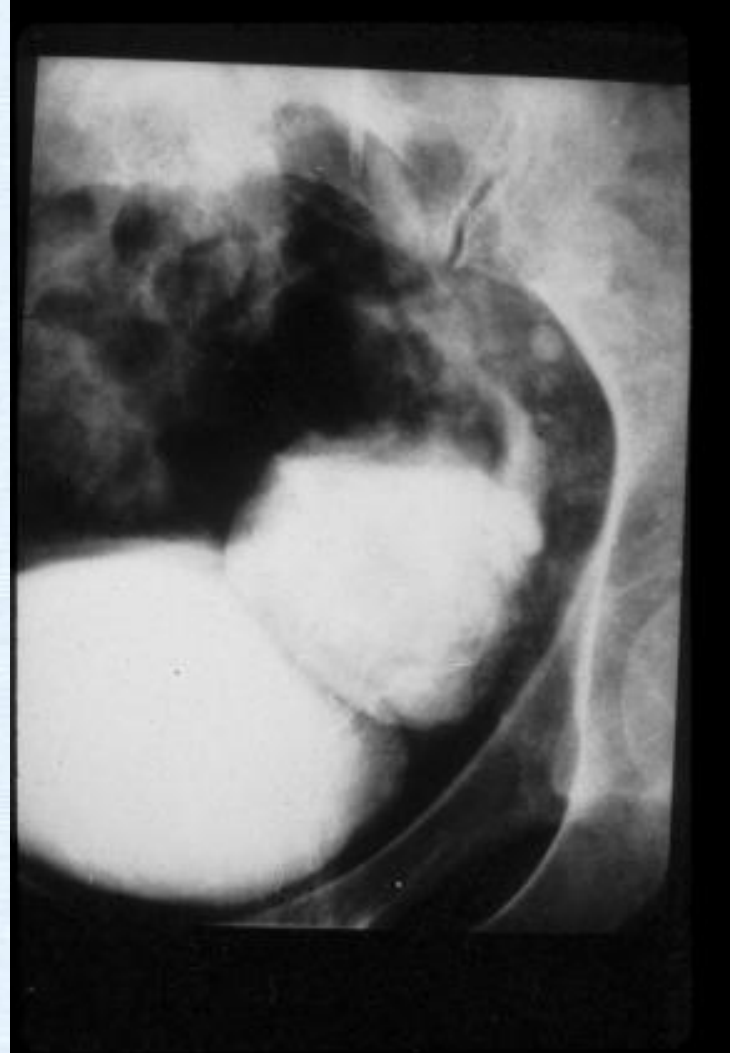
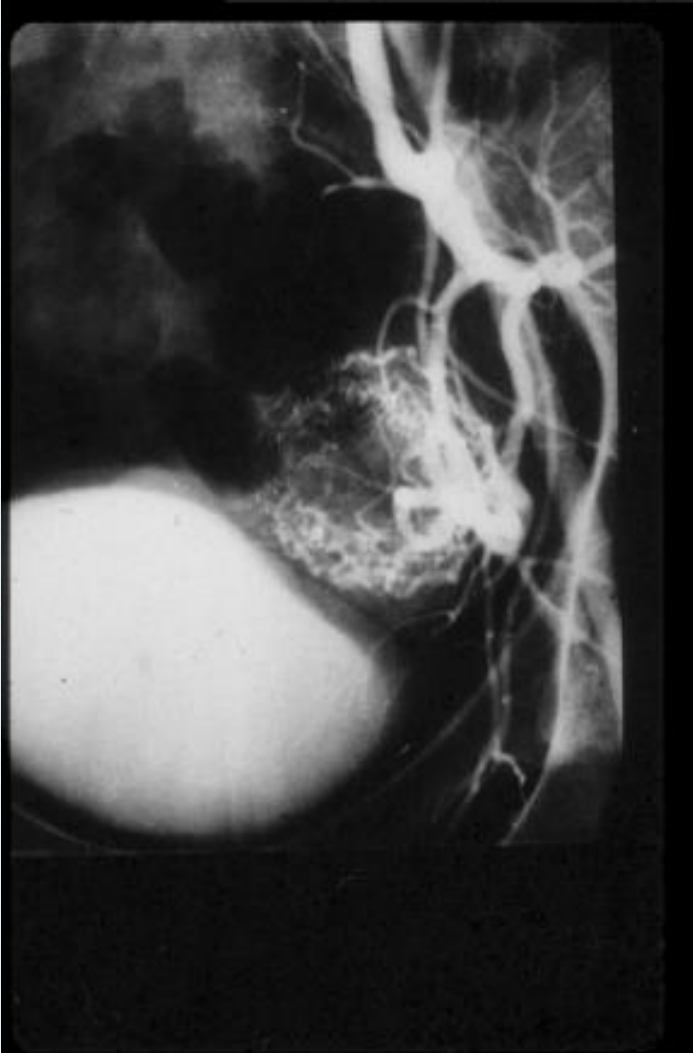
What is the most likely diagnosis ?

- A---overlying metallic objects
- B---metastases from mucinous colon carcinoma
- C---prostate metastases
- D---artifact from colon filled with barium

Case # 26

28 Year old infertile Woman with Left Adnexal Mass

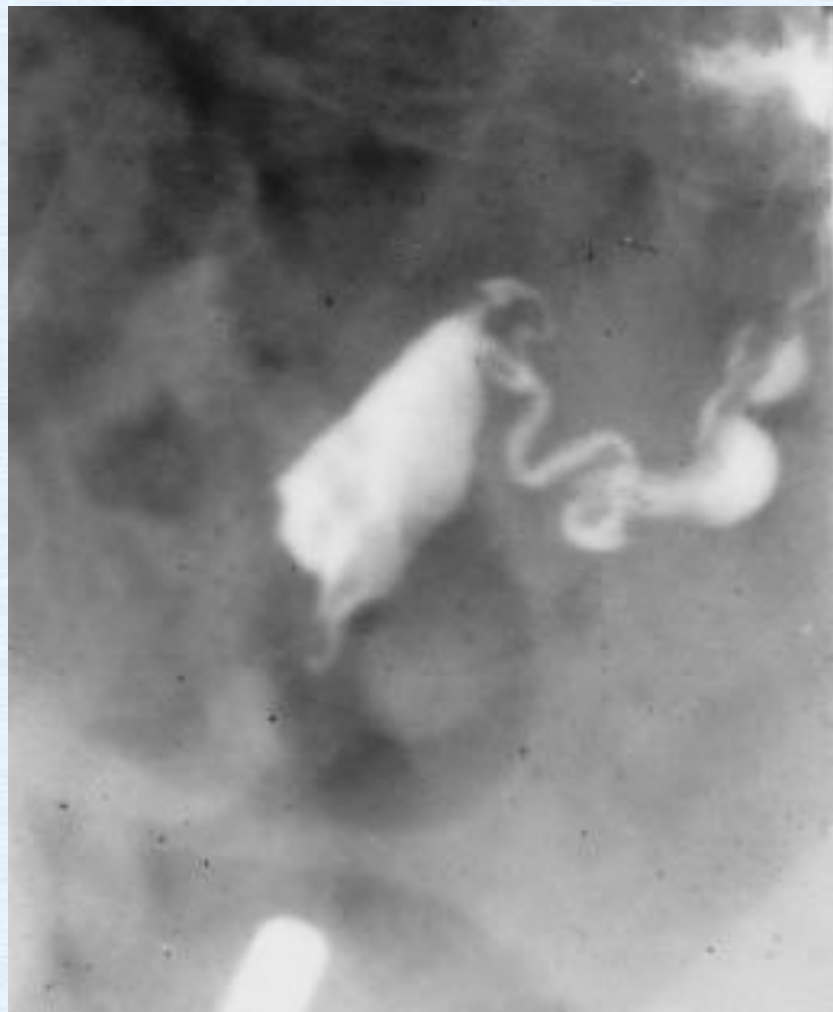


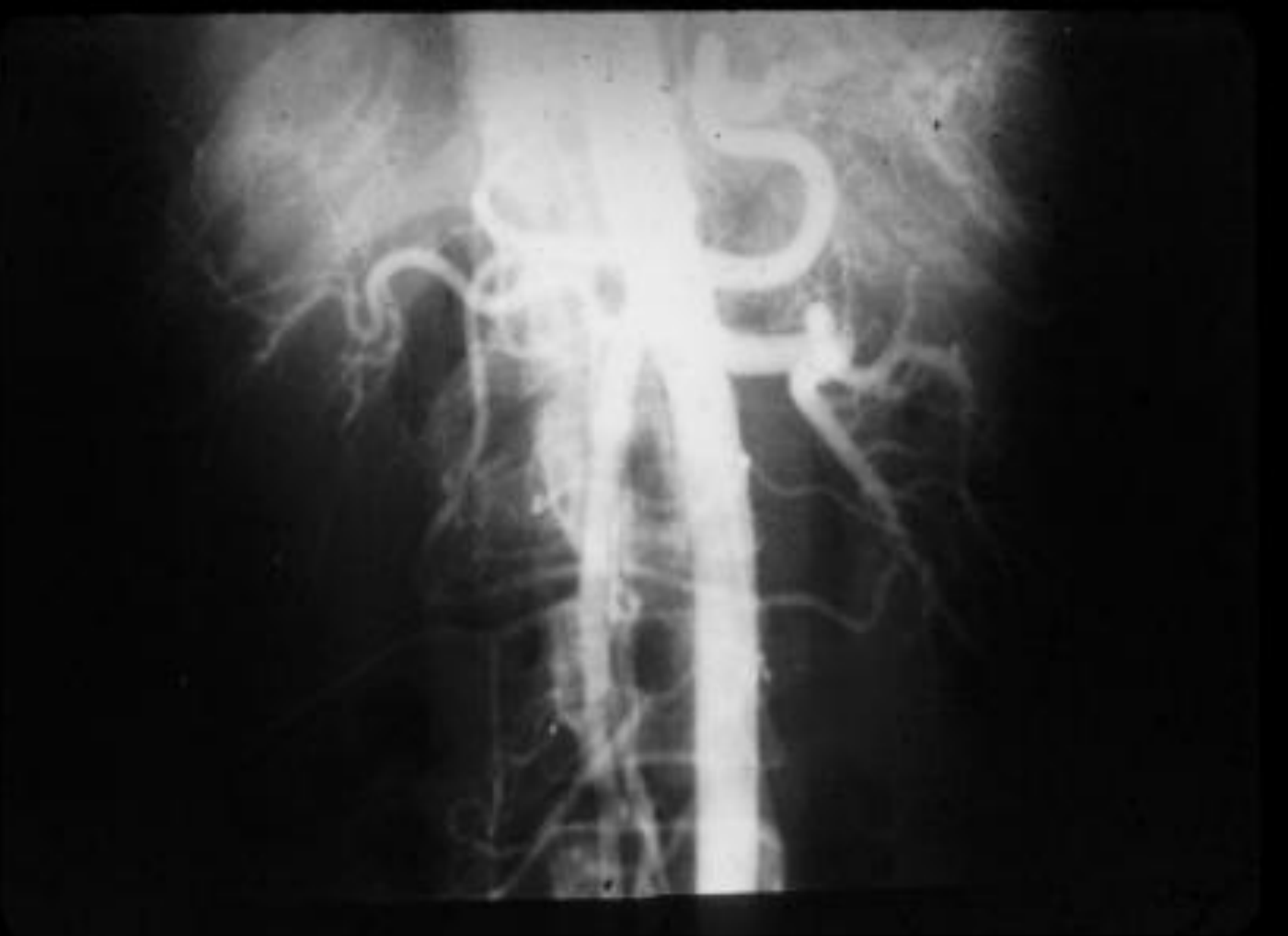
医学会核医学分会
术与继续教育学组

What is the diagnosis?

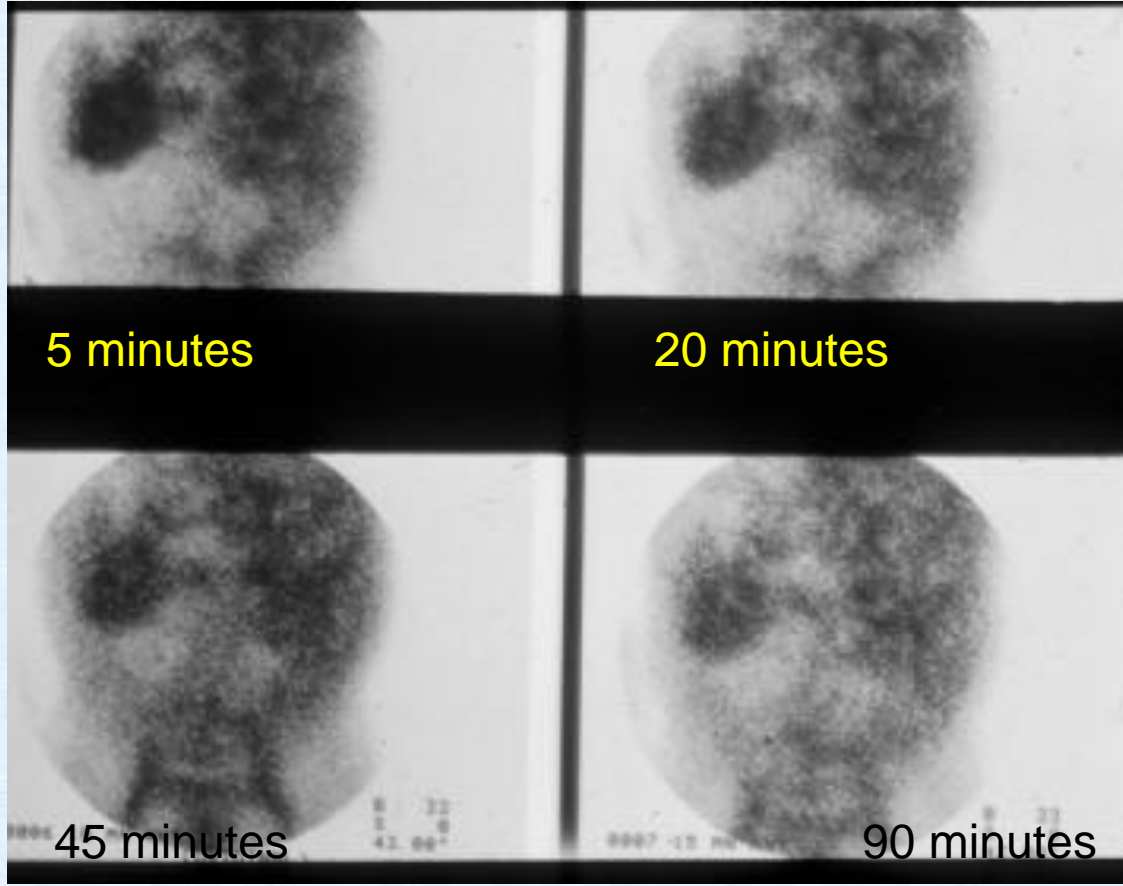
- A---ovarian neoplasm
- B---congenital hemi-agenesis of G-U tract
- C---teratoma
- D---giant hemangioma





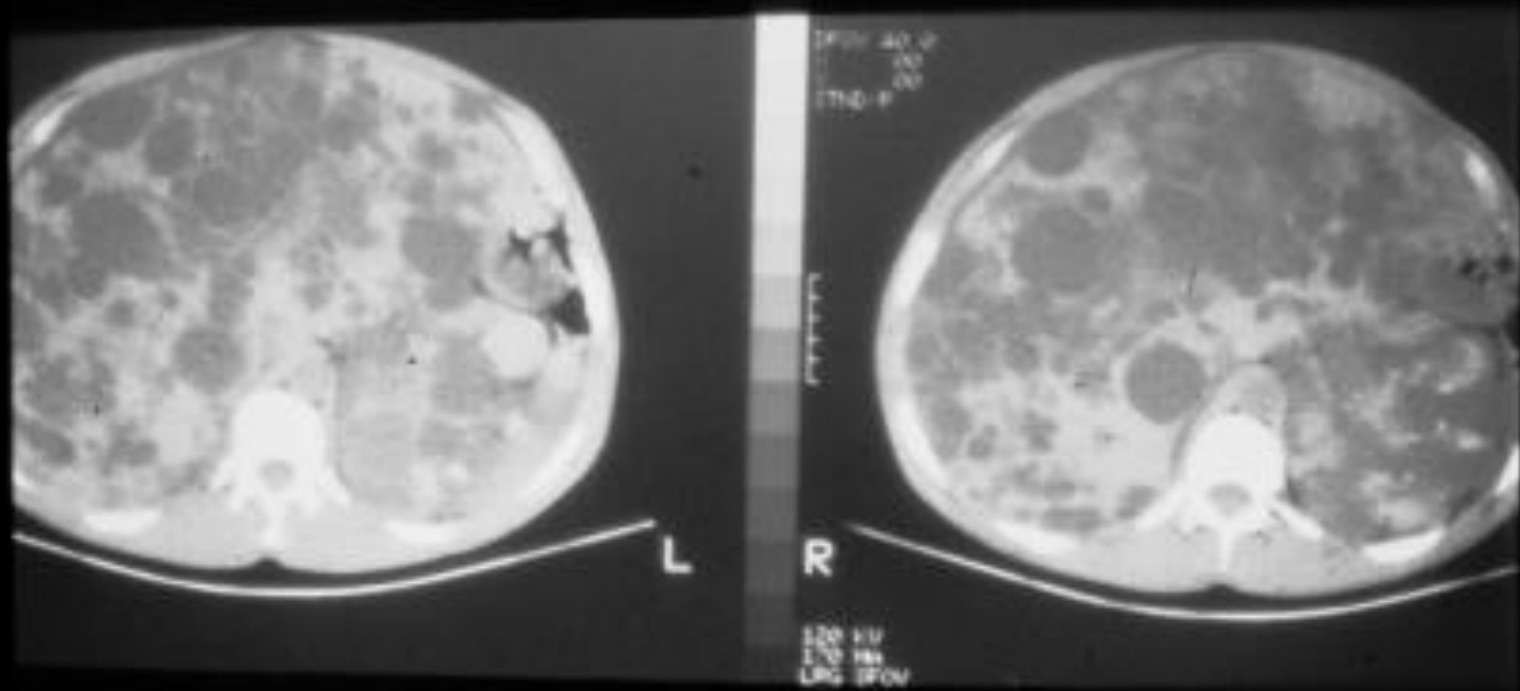
Case # 27

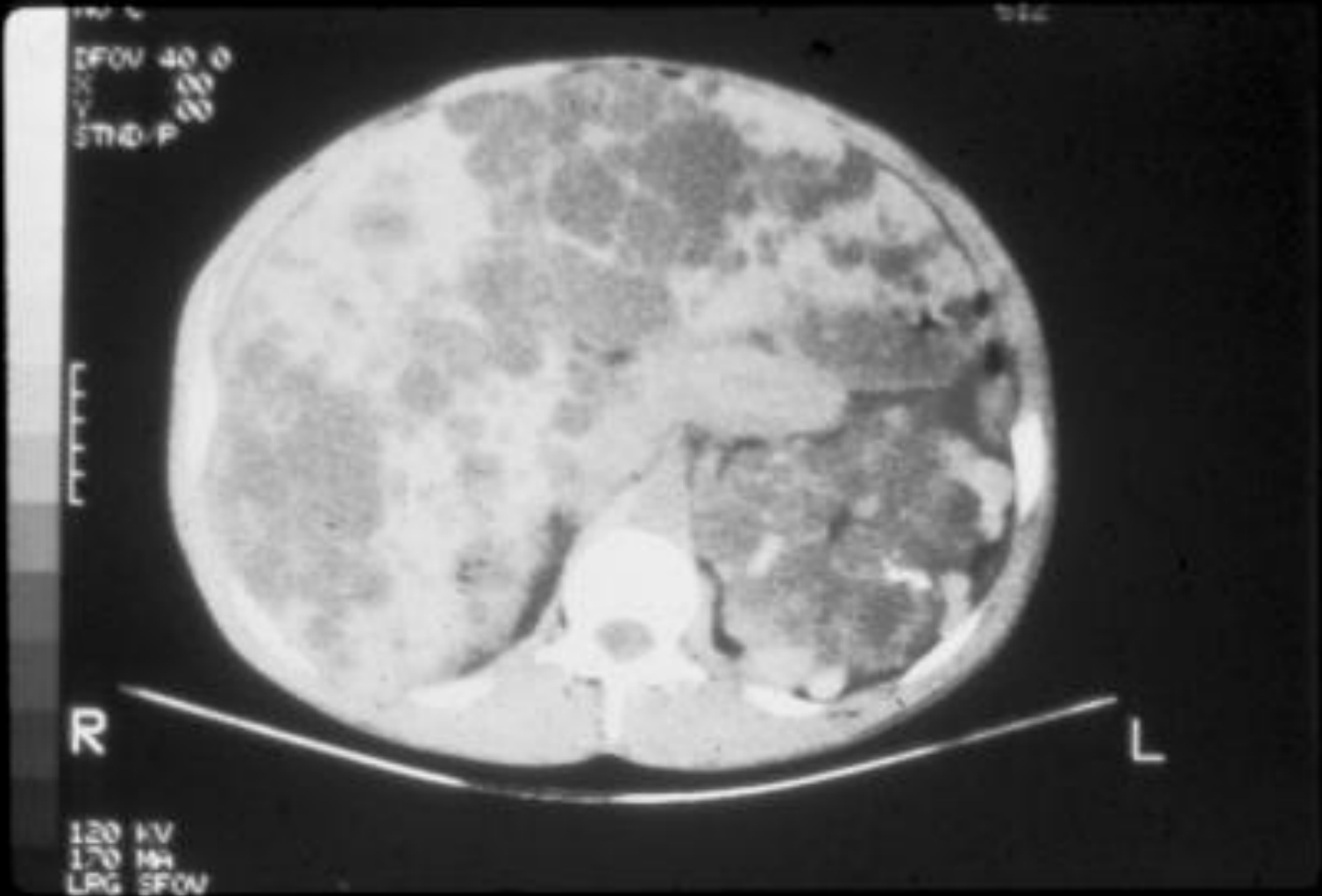
54 Year old Man with Lower G-I Bleed



What is the diagnosis ?

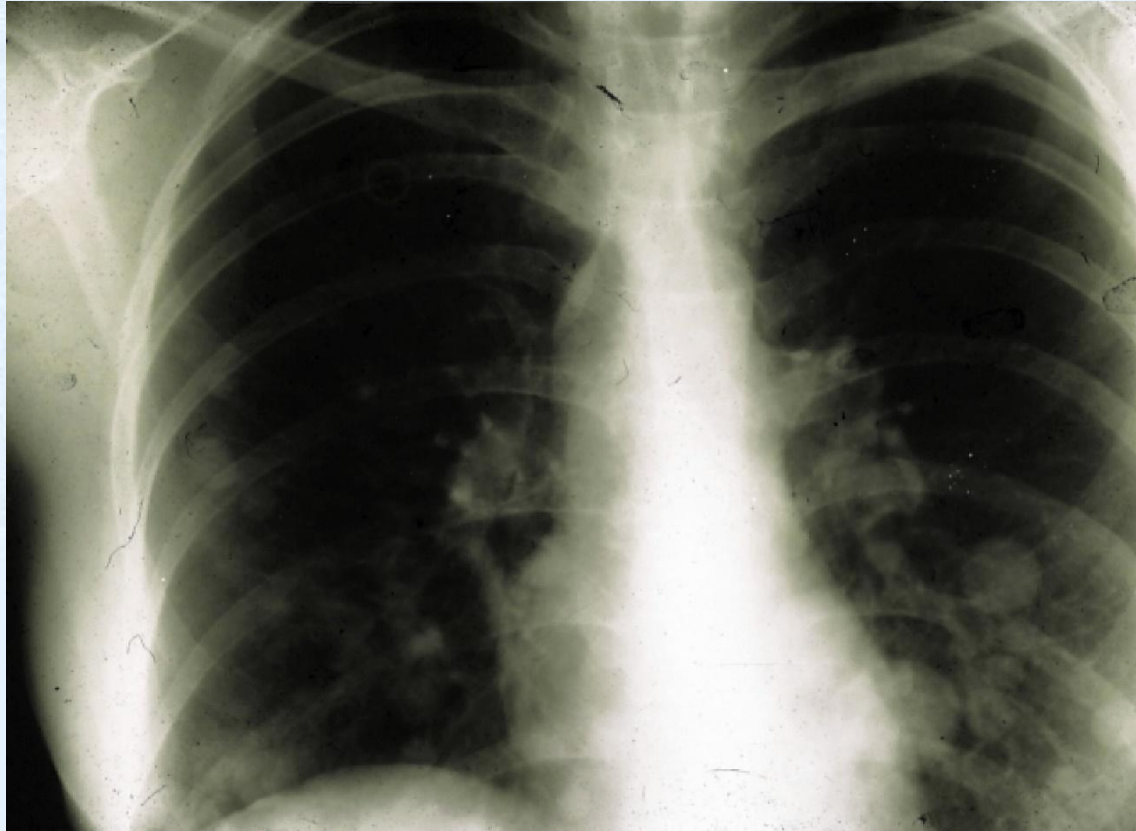
- A---small bowel bleed
- B---peritoneal carcinomatosis
- C---multiple cysts of abdominal organs
- D---multiple vascular malformations





Case # 28

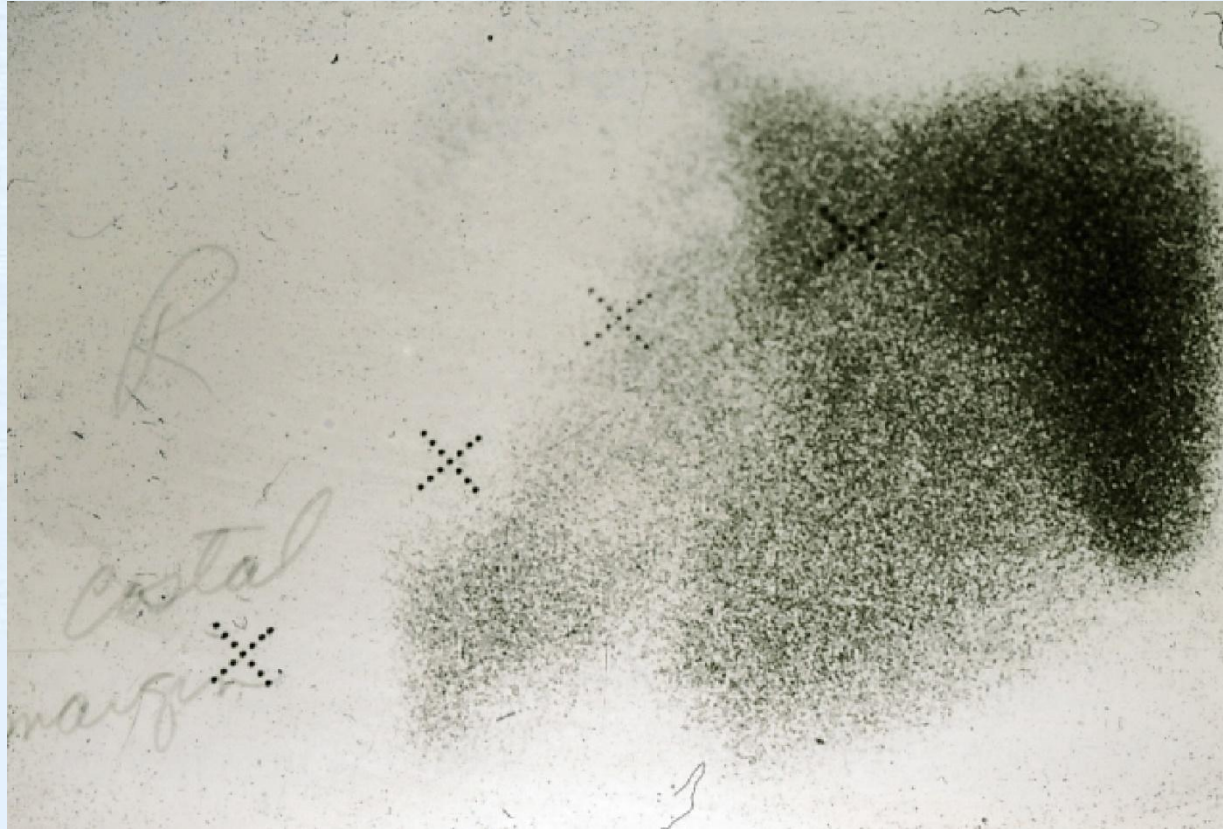51 year old woman with history of alcohol abuse



51 year old woman with history of alcohol abuse



中华医学会核医学分会
技术与继续教育学组

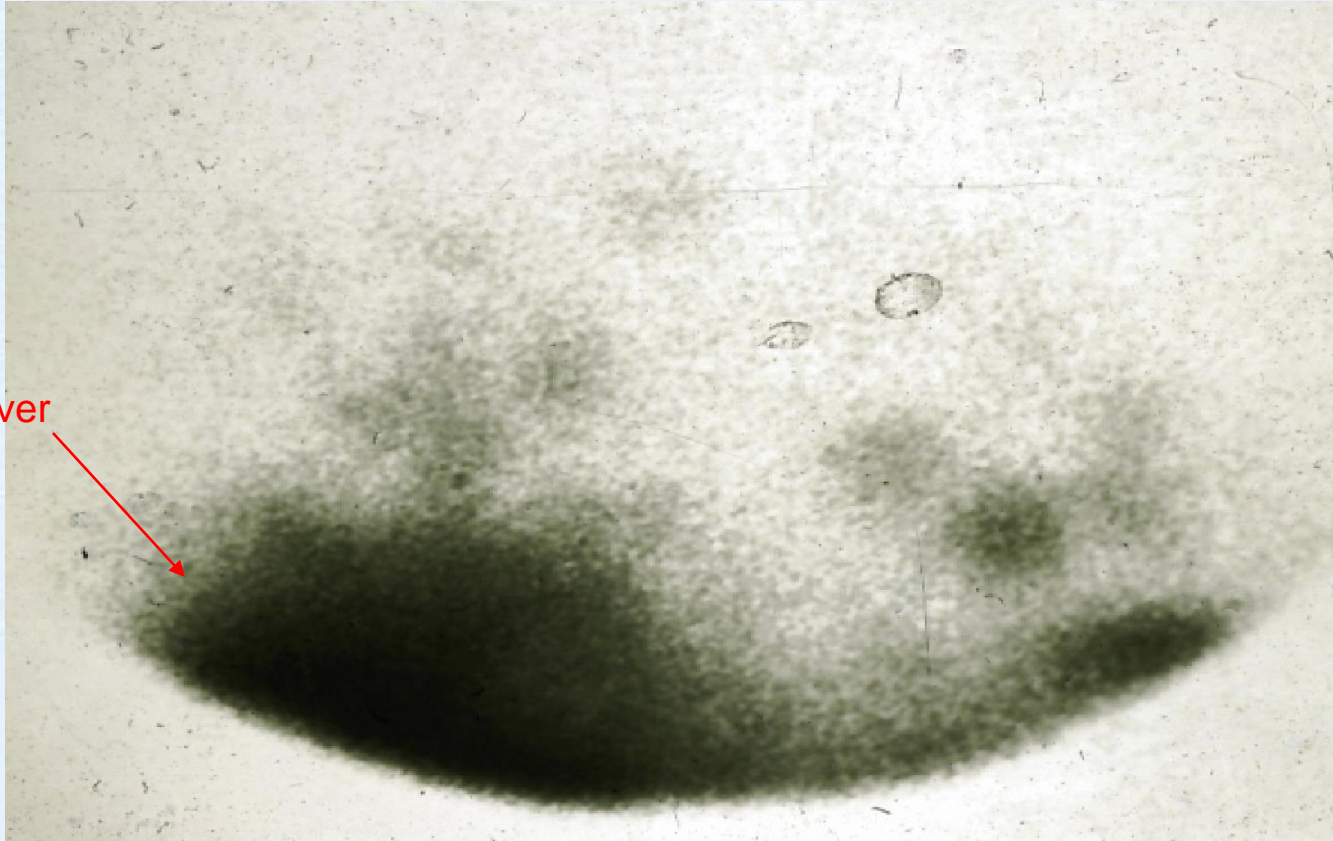


Tc-99m sulfur colloid

51 year old woman with history of alcohol abuse



中华医学会核医学分会
技术与继续教育学组



Liver

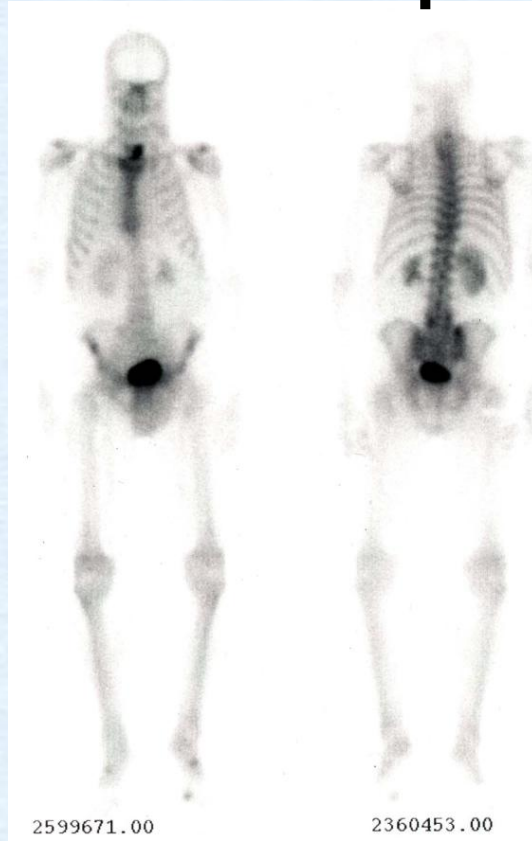Tc-99m IDA

What is the diagnosis ?

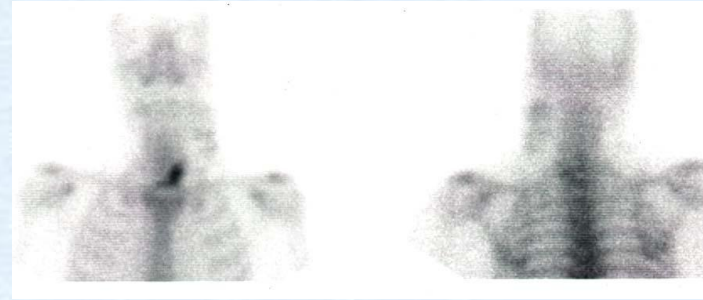
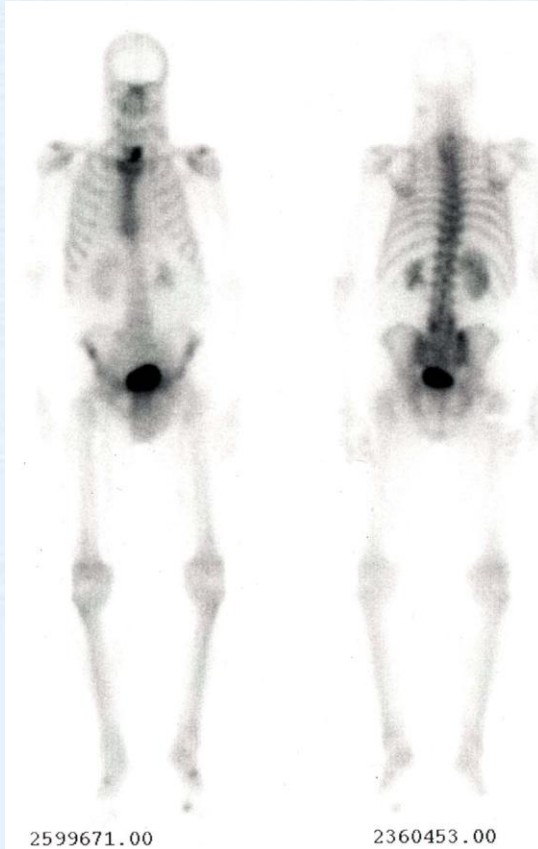- A---functional metastases from hepatoma
- B---radiochemical impurity
- C---misinjection (wrong radiopharmaceutical given)
- D---none of the above

Case # 29

71 year old man with prostate cancer



71 year old man with prostate cancer

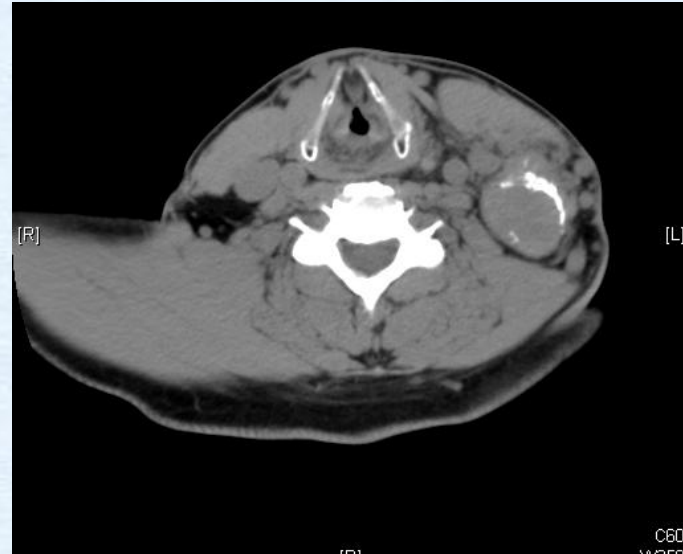
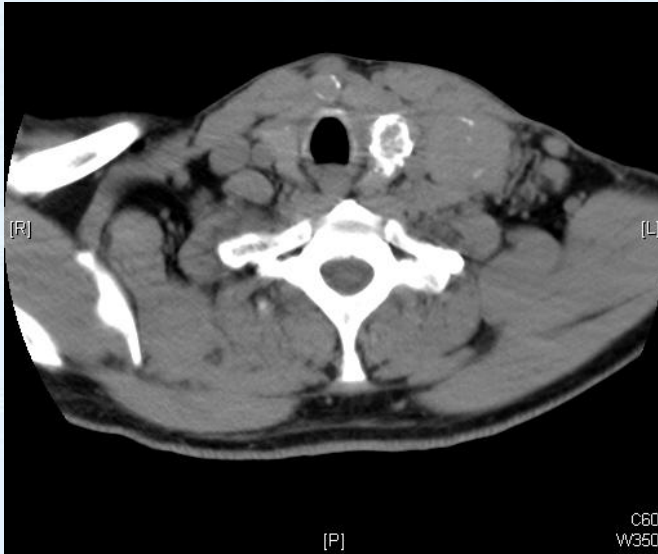




What is the most likely diagnosis?

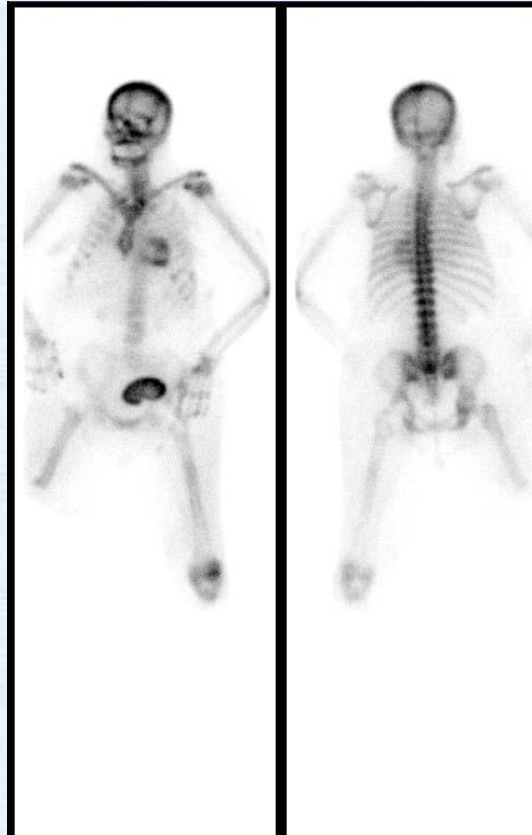
- A---normal thyroid and hyoid cartilage activity
- B---uptake around infected tracheostomy site
- C---thyroid carcinoma
- D---post surgical scar
- E---none of the above

71 year old man with prostate cancer who also had a known past history of untreated thyroid cancer



Case # 30

68 y/o man with advanced Diabetes Mellitus



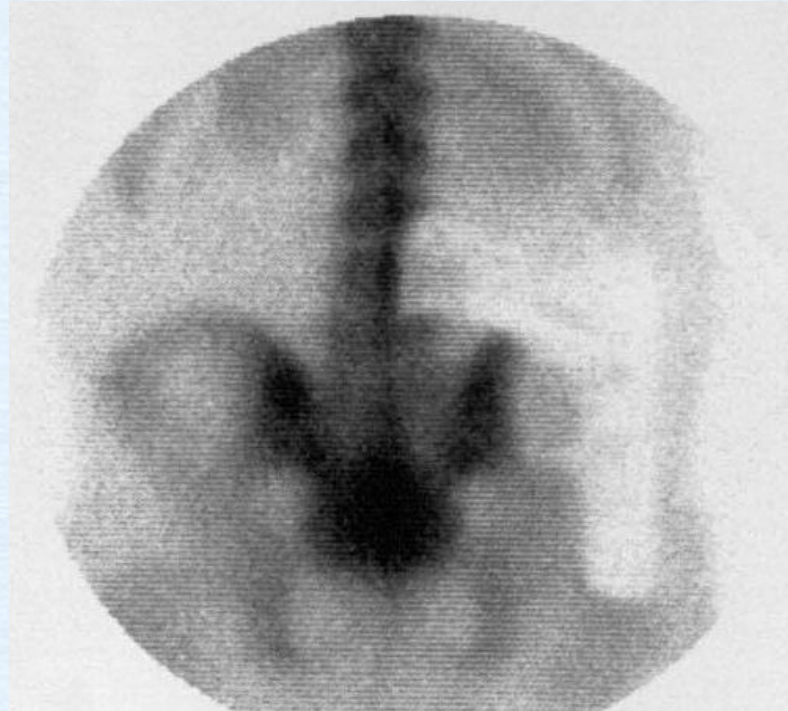


What is the most likely diagnosis ?

- **A---congenital heart disease**
- **B---traumatic injury**
- **C---acute myocardial infarct**
- **D---amyloidosis**

Case # 31

35 year old man with right buttocks discomfort



What is the most likely diagnosis?

- A---fell and hurt himself after robbing a bank
- B---doesn't like doctors and is preparing for the worst
- C---just found out that his girlfriend has been unfaithful
- D---returned from target practice and forgot to empty his pockets
- E---all of the above may be true

中华医学会核医学分会第十一届委员会 技术与继续教育学组成员名单

组 长	姚稚明、缪蔚冰
副组长	王茜、范岩、刘纯
传媒管理	林端瑜、余飞
秘 书	李旭、郑山
委 员	陈亮、杨治平、肖茜、李梦春、郑堃、李从心、王闯、程兵、黄斌豪、邓群力、袁梦晖、边艳珠、李忠原、黄占文、张卫方、李凤岐、褚玉、潘建英、程祝忠、梅丽努尔·阿布都热西提、肖欢、耿建华、武兆忠、杨吉琴、农天雷、徐微娜、苏莉、江勇、董萍、黄谋清、马宏星、向阳