



# 中华医学会核医学分会第十一届委员会 技术与继续教育学组

## 北京继续教育疑难病例分析展示

# Interesting and Unusual Cases (19-24)

专家姓名: Leonard Freeman MD, PhD

专家单位: Division of Nuclear Medicine,  
Albert Einstein College of Yeshiva University



中华医学会核医学分会  
技术与继续教育学组

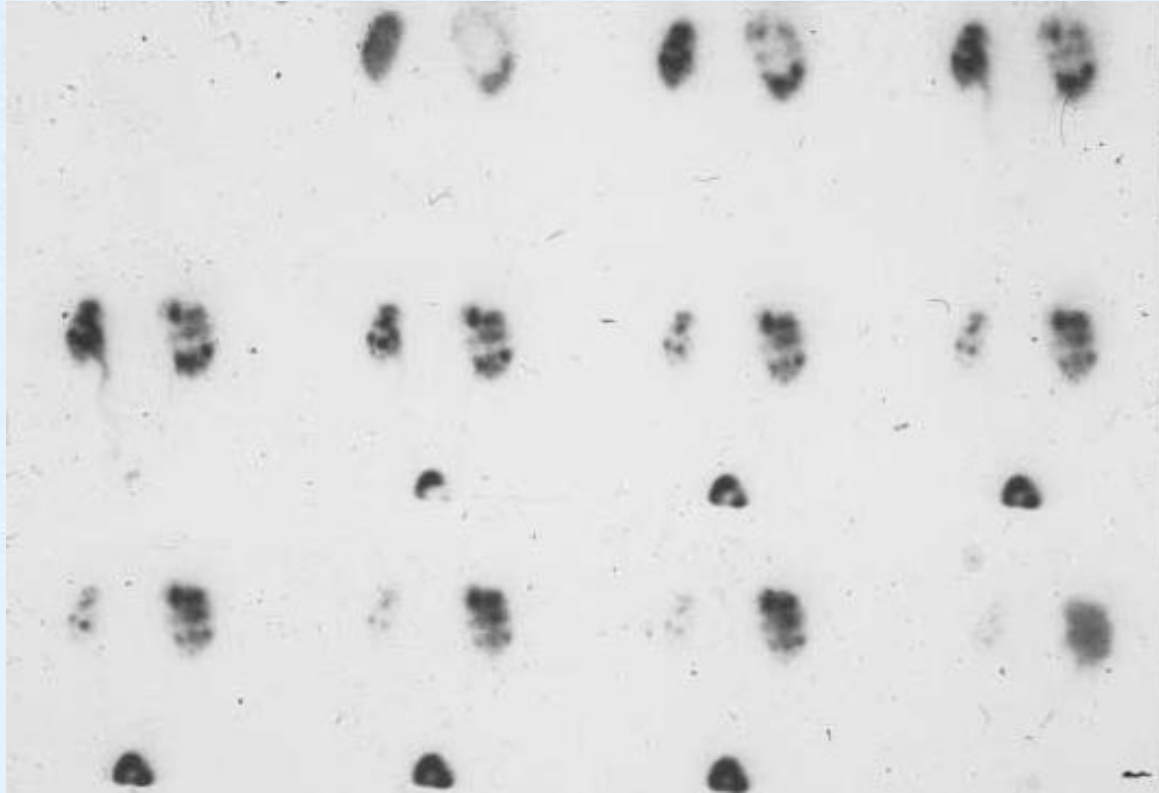


Albert Einstein College of Medicine  
OF YESHIVA UNIVERSITY



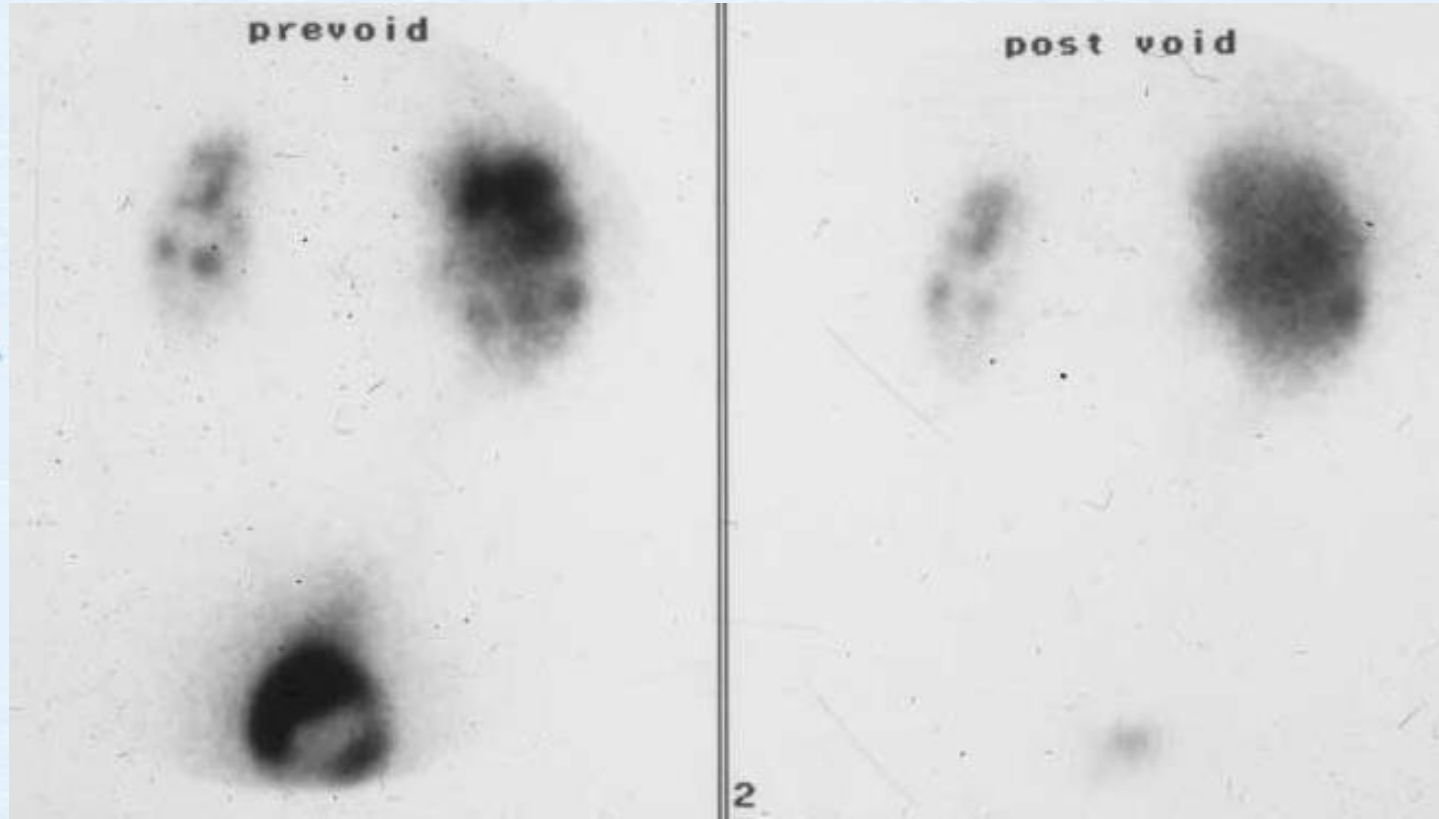
# Case # 19

## 48 year old man with recurrent urinary infections



$^{99m}\text{Tc}$ -MAG 3

# 48 year old man with recurrent urinary infections



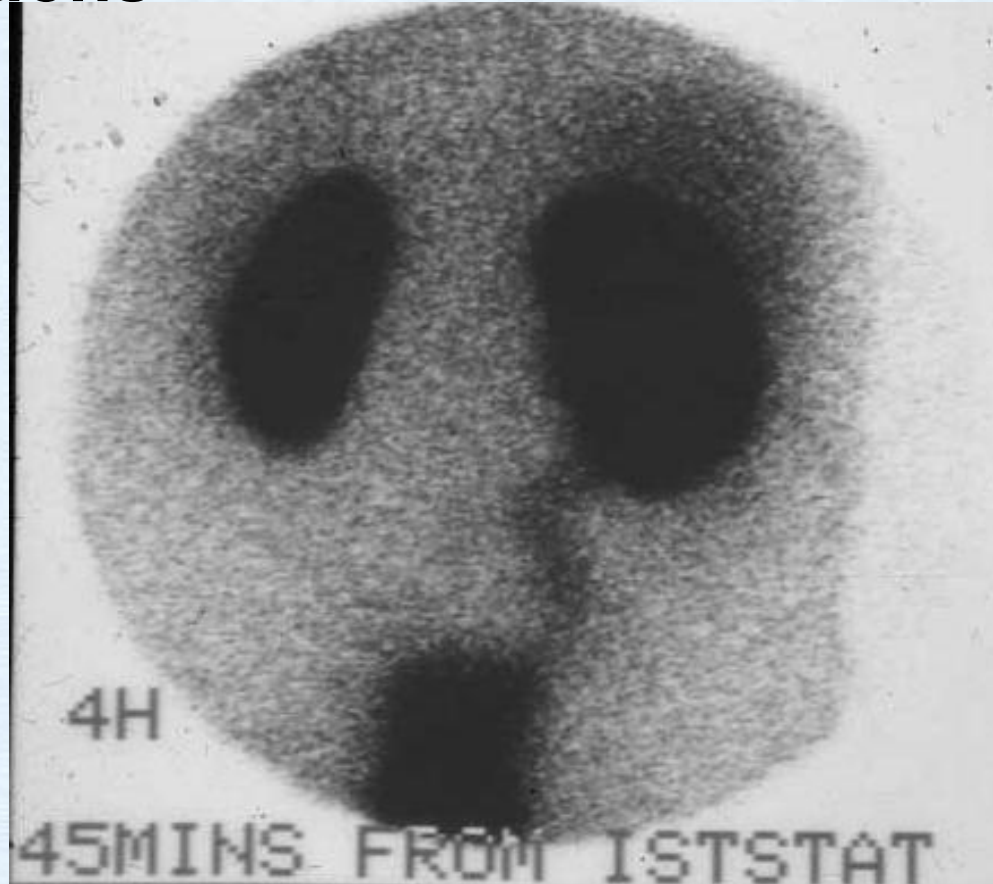
What is the diagnosis?

- A---ectopic ureterocele
- B---multiple renal cysts
- C---ureteral carcinoma
- D---congenital caliectasis

# 49 year old man with recurrent urinary infections



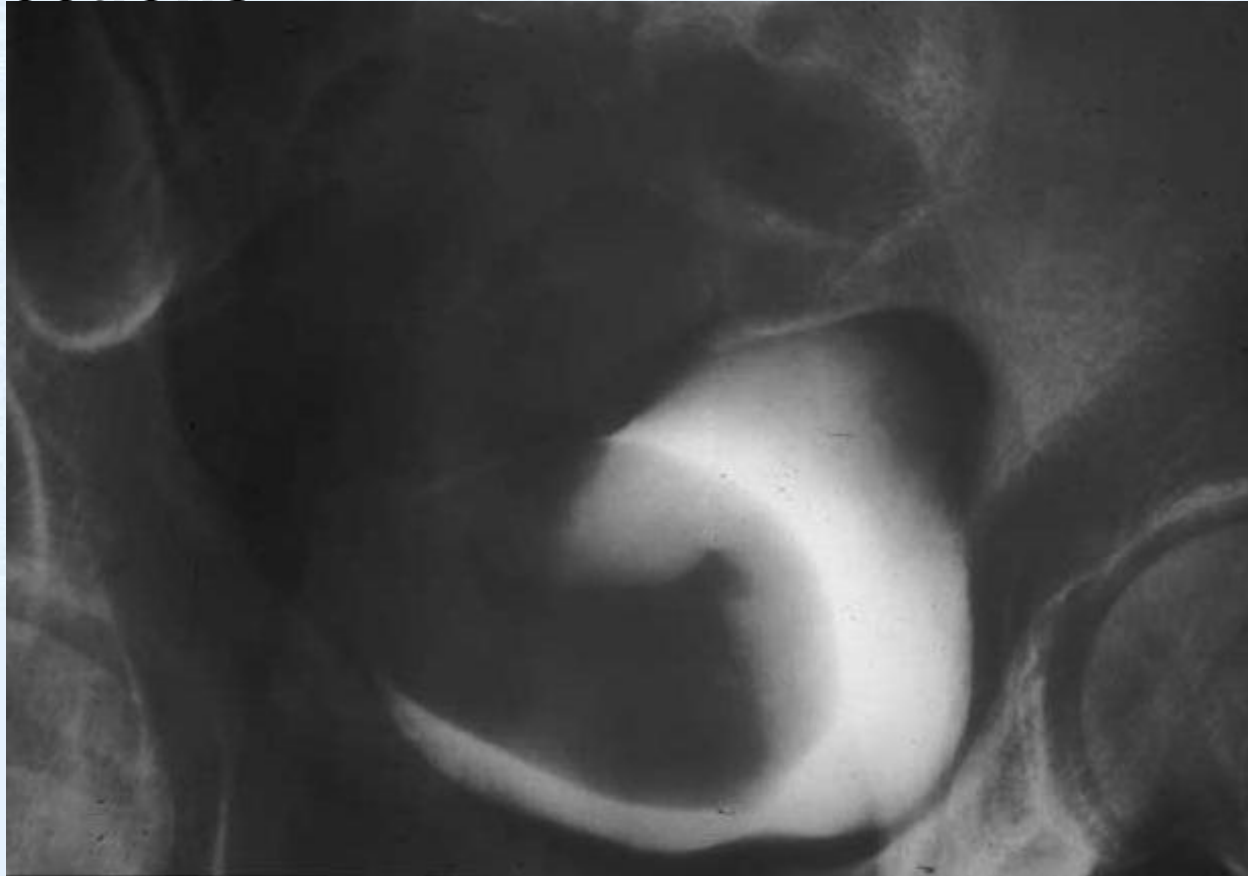
中华医学会核医学分会  
技术与继续教育学组



# 49 year old man with recurrent urinary infections

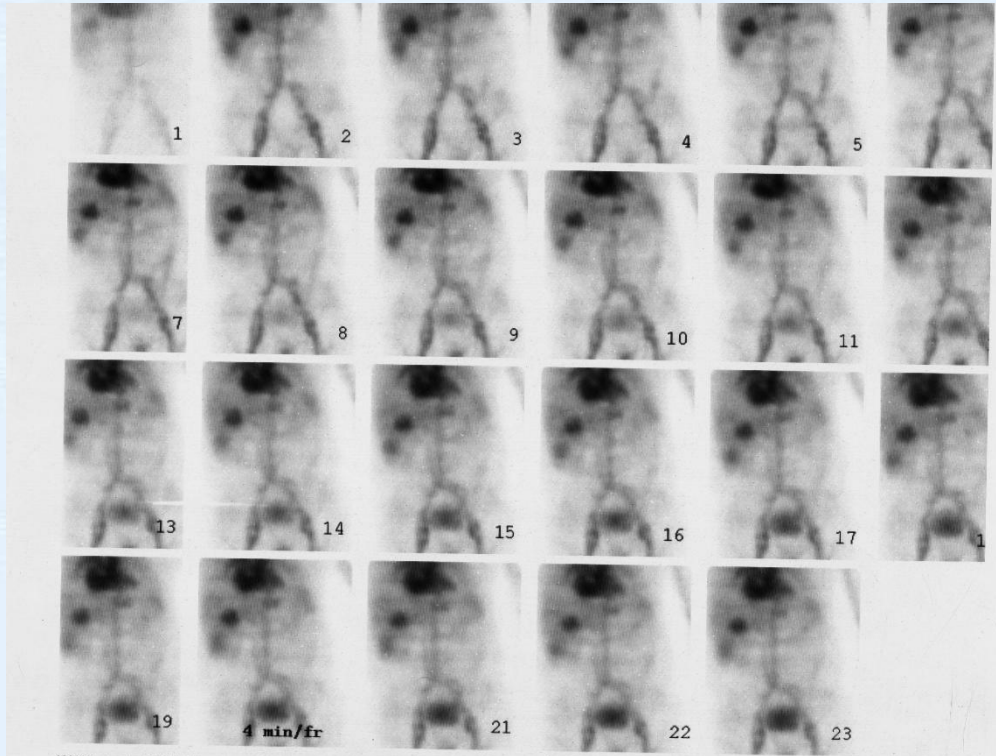


中华医学会核医学分会  
技术与继续教育学组

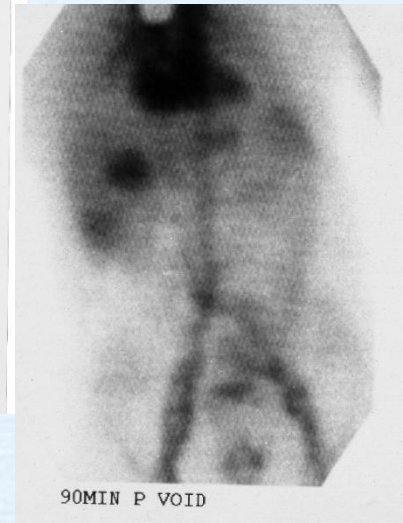

# Case # 20

## 44 year old man with acute rectal bleeding



99mTc-RBC's





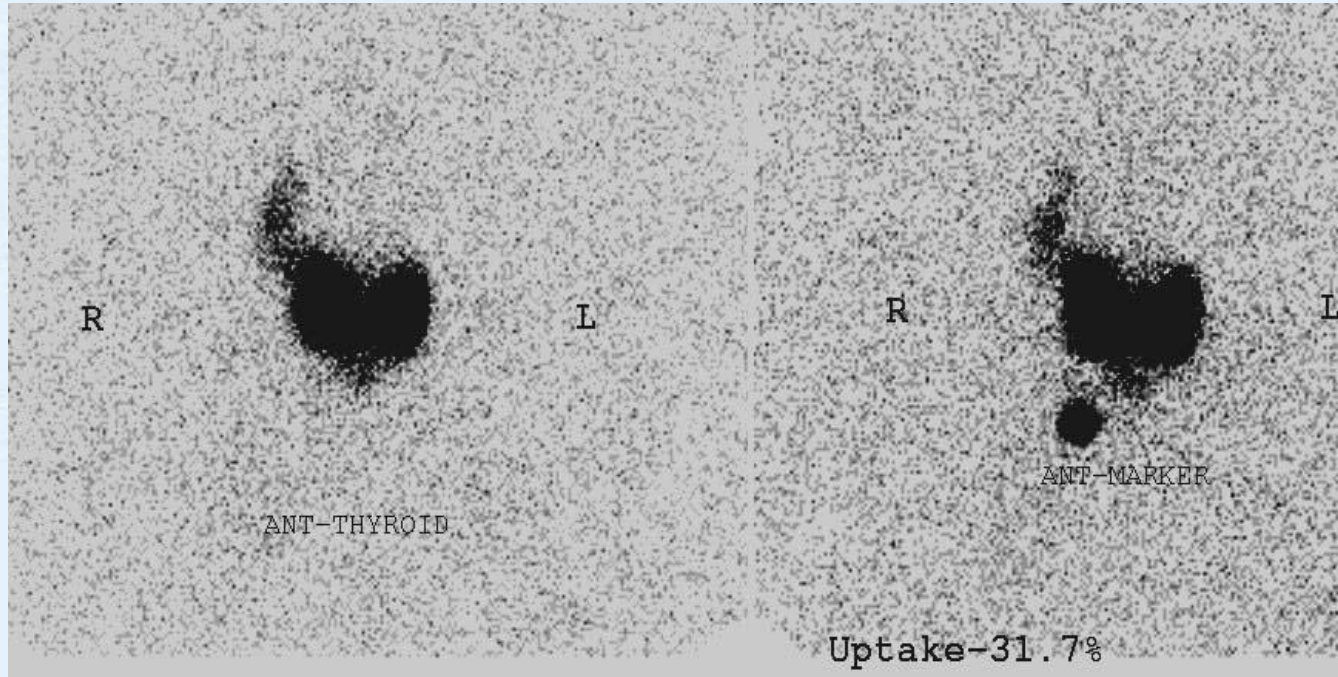


# What is the most likely diagnosis ?

- A---multiple hepatic adenomas
- B---multiple hepatic hemangiomas
- C---descending colon bleed
- D---A & C are correct
- E---B & C are correct

# case # 21

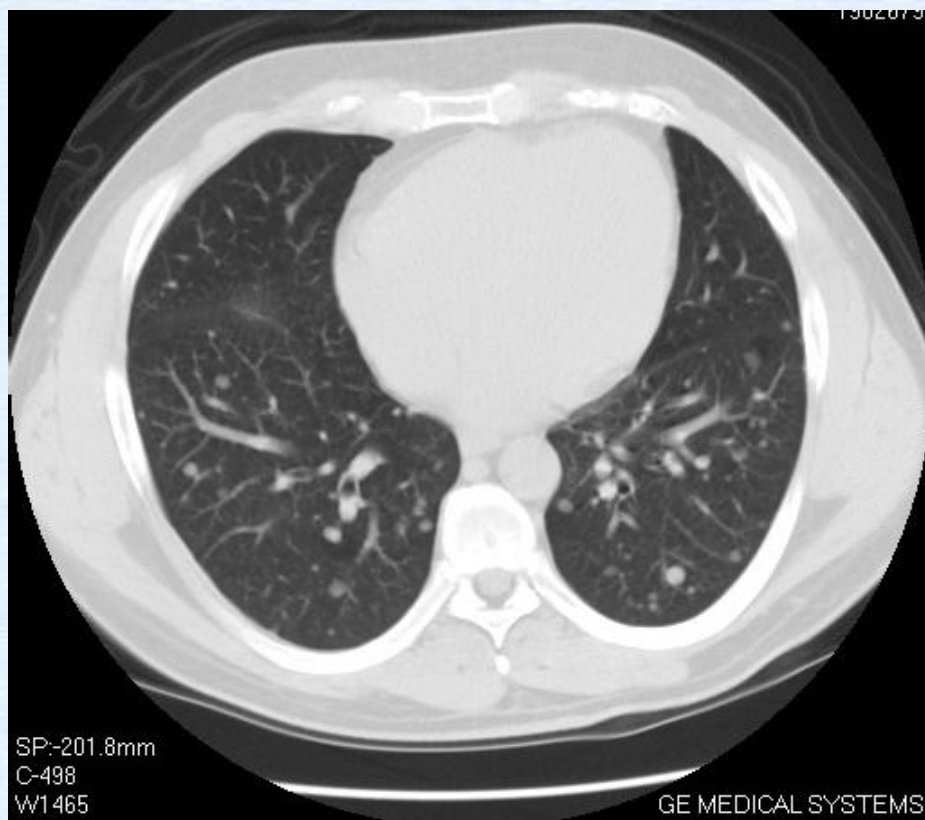
## 38 year old man with multiple lung nodules



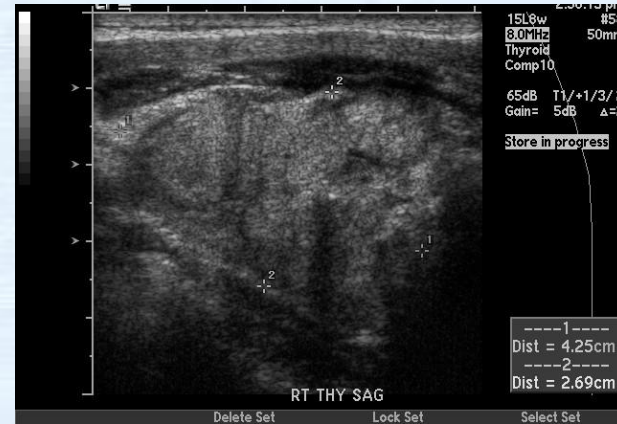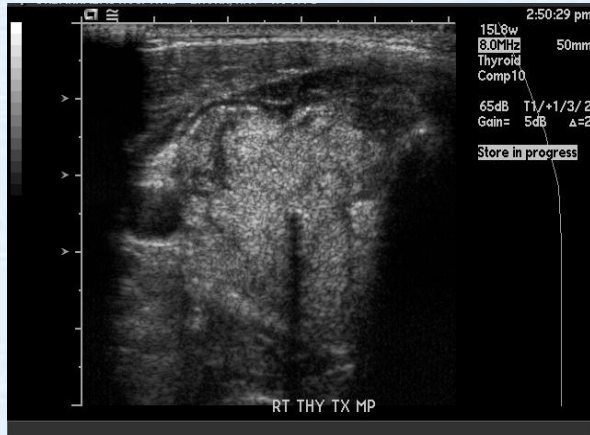


# What is the most likely diagnosis ?

- A---pyramidal lobe of thyroid gland
- B---irregular asymmetric right lobe enlargement
- C---lateral aberrant thyroid
- D---normal variant asymmetry

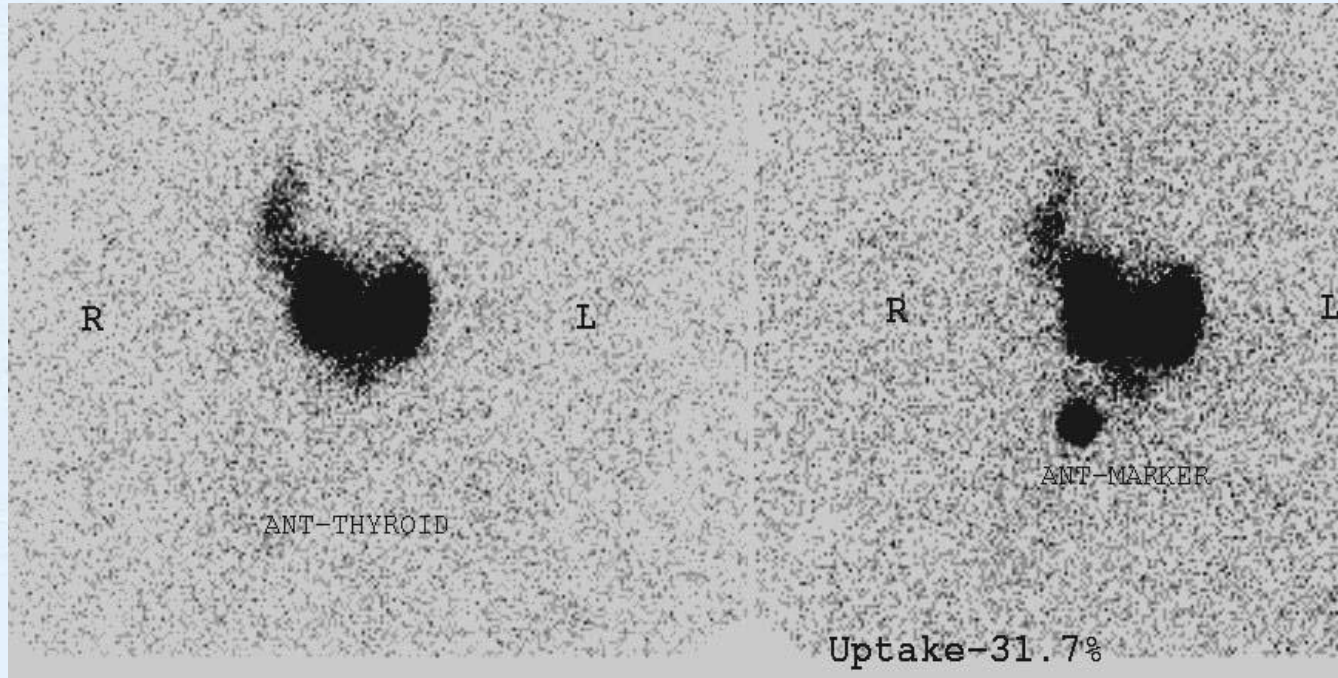


right lobe nodule and another superior pole nodule were biopsied



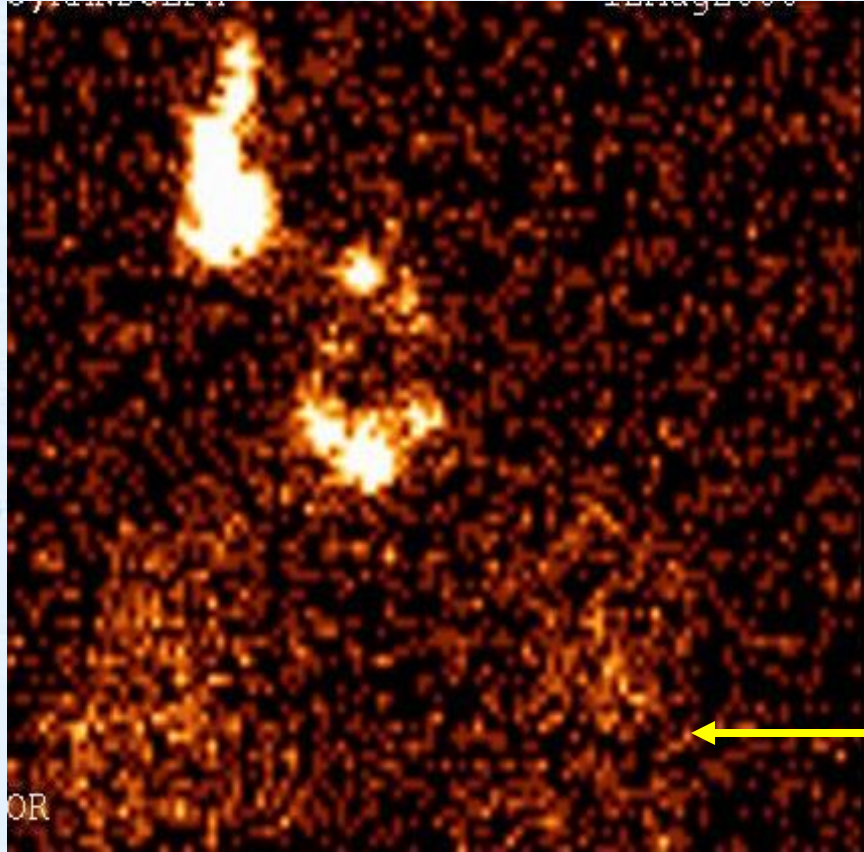
- *FNA* - dominant nodule (R lobe) Adenomatous goiter

## I-123 Thyroid scan (f/u after Negative FNA and findings prompted further surgery)



Pathology revealed multi-focal papillary cancer with follicular differentiation

# Post thyroidectomy Pre I-131 therapy




RAIU = 20 %

← Lung activity

subsequent right neck dissection revealed 5/7 positive nodes



# 7 Days Post 200mCi I-131 therapy





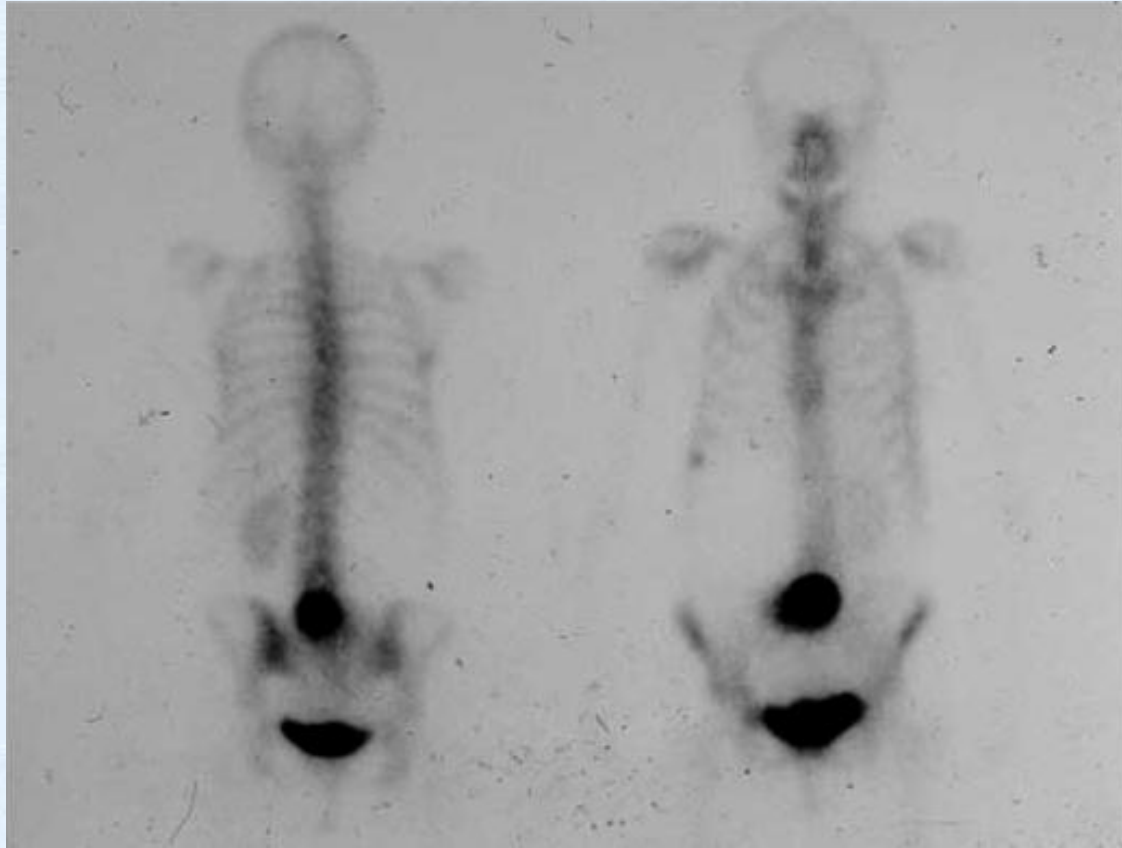

# Lateral Aberrant Thyroid

- Metastasis from an occult primary thyroid carcinoma
- Usually a nodal metastatic disease from a thyroid papillary cancer detected due to the lateral neck mass/swelling, and rarely a primary arising in the aberrant thyroid rest cells (embryogenic rests versus metastatic theory).
- Some claim the benign nature of these embryogenic thyroid cells.
- Case point: warrants further investigation to rule out neoplasm

# Case # 22

## 48 year old woman with breast Cancer

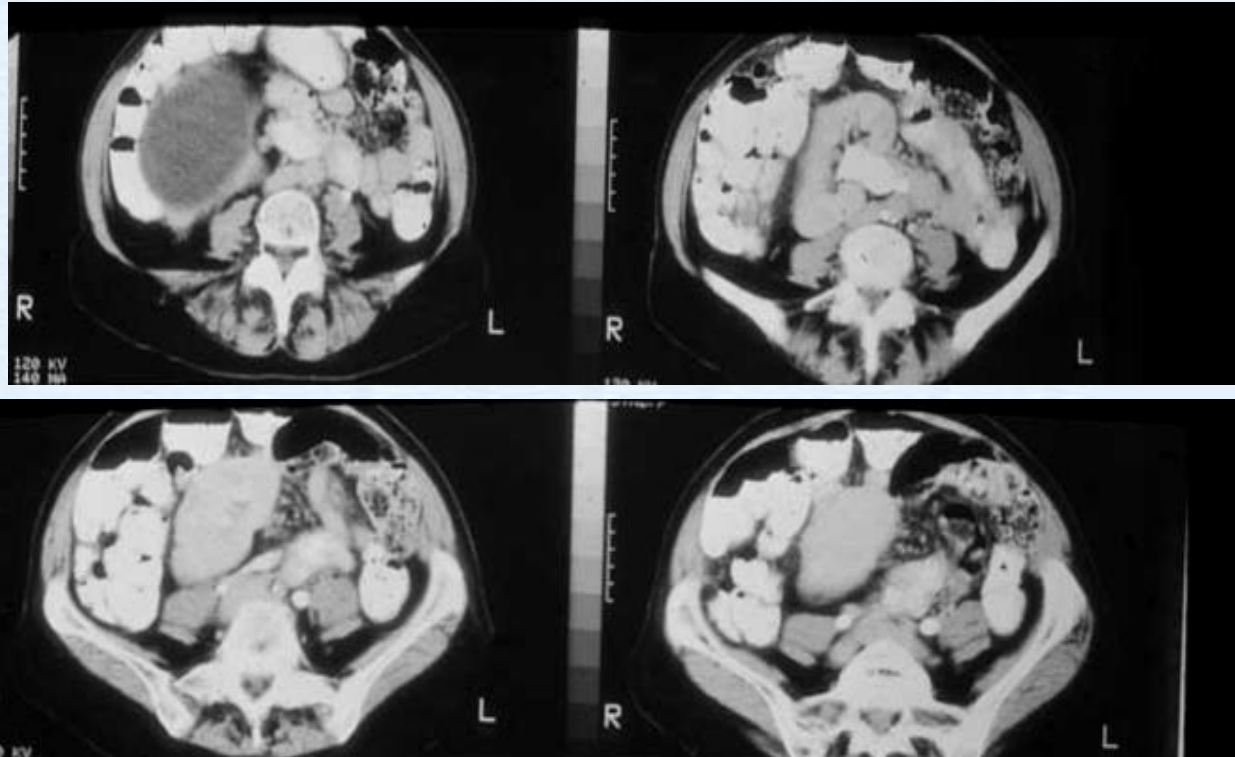




# What is the most likely diagnosis ?

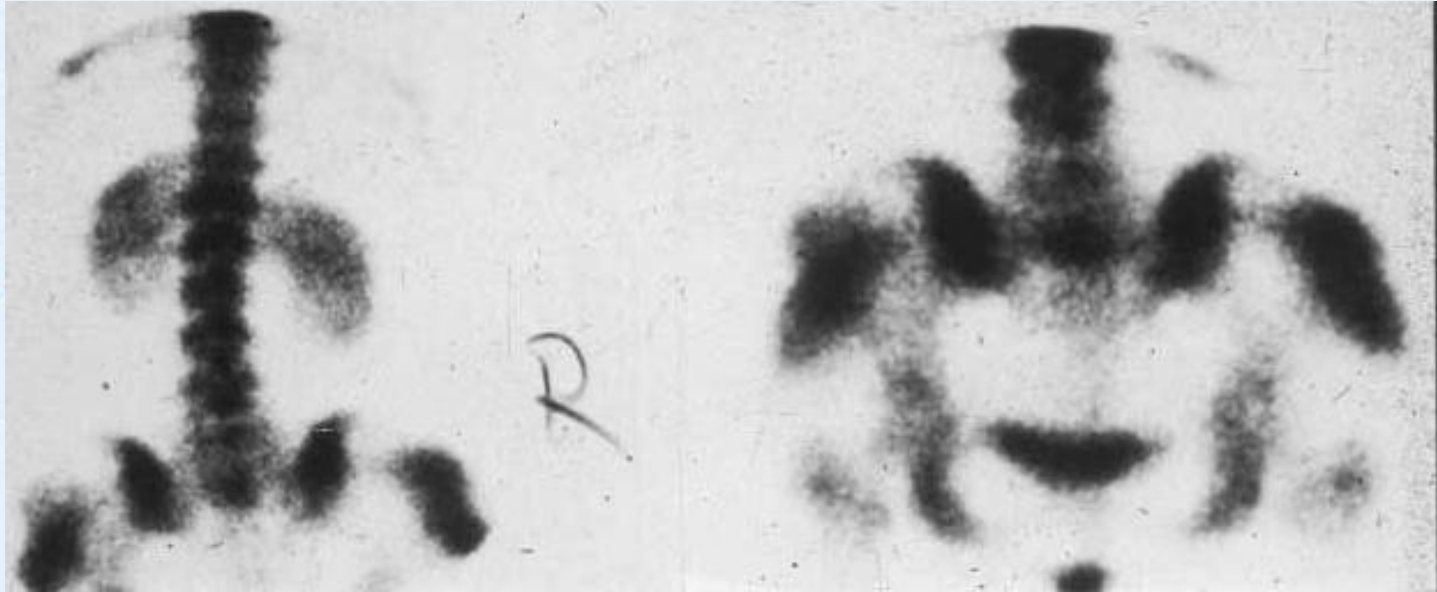
- A--- kidney displaced to pelvis
- B---vascular metastasis to pelvis
- C---calcified fibroid
- D---congenital pelvic kidney

# 48 year old woman with breast cancer



# Case # 23

67 year old anemic woman

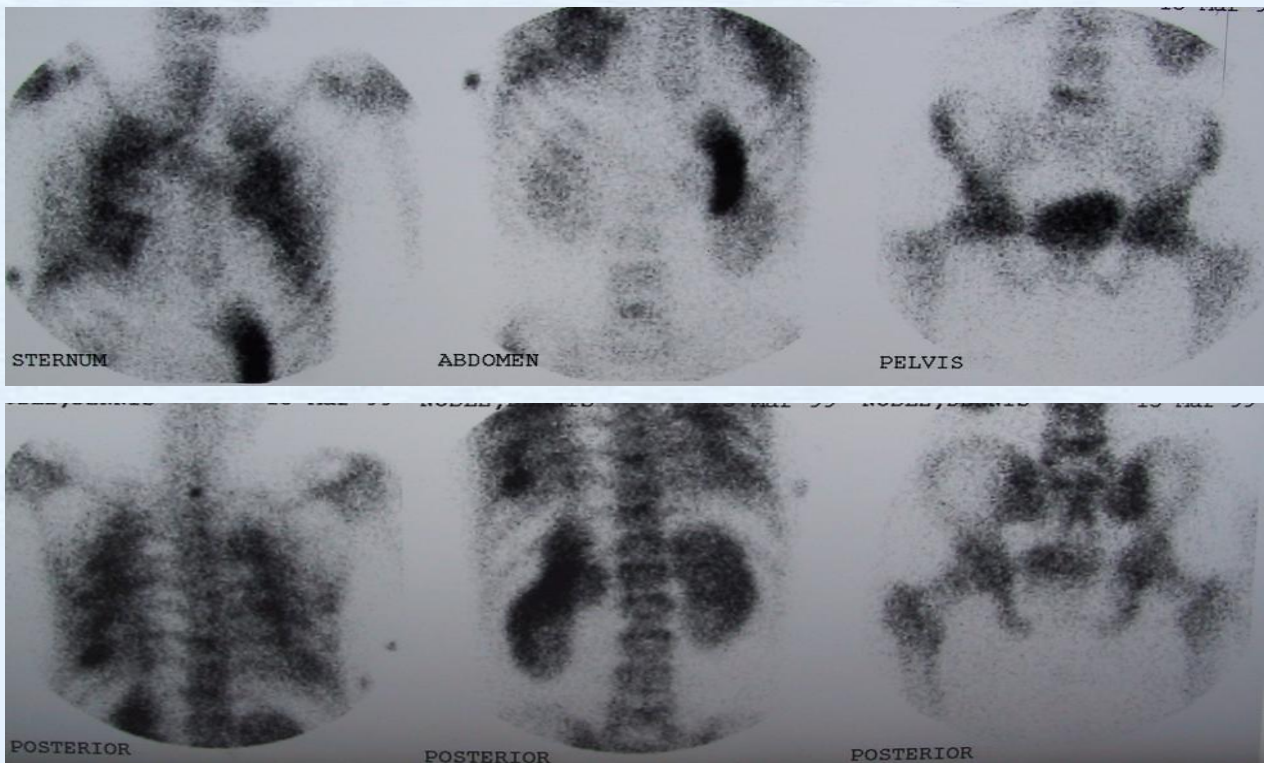


What is the diagnosis ?

- A---iron injections
- B---bilateral iliac wing exostoses
- C---dermatomyositis
- D---rhabdomyolysis

# Case # 24

## 49 year old man





# What is the most likely diagnosis ?

- A---residual activity from prior scan
- B---radiochemical impurity
- C---hyperparathyroidism
- D---free pertechnetate



# 中华医学会核医学分会第十一届委员会 技术与继续教育学组成员名单

组 长	姚稚明、缪蔚冰
副组长	王茜、范岩、刘纯
传媒管理	林端瑜、余飞
秘 书	李旭、郑山
委 员	陈亮、杨治平、肖茜、李梦春、郑堃、李从心、王闯、程兵、黄斌豪、邓群力、袁梦晖、边艳珠、李忠原、黄占文、张卫方、李凤岐、褚玉、潘建英、程祝忠、梅丽努尔·阿布都热西提、肖欢、耿建华、武兆忠、杨吉琴、农天雷、徐微娜、苏莉、江勇、董萍、黄谋清、马宏星、向阳